



Case Report Microbiology

## Multidrug-Resistant *Corynebacterium* spp., *Escherichia coli*, and *Klebsiella* spp. Isolated from the Lungs of a Six-Year-Old Arewa Stallion

Talatu Patience Markus<sup>1</sup>, Ochuko Orakpoghenor<sup>2</sup>, Paul Habila Mamman<sup>3</sup>

<sup>1</sup>Microbiology Specialty, Pathology Faculty, College of Veterinary Surgeons of Nigeria, Zaria Study Centre, <sup>2</sup>Diagnostic Pathology Specialty, Pathology Faculty, College of Veterinary Surgeons of Nigeria, Zaria Study Centre, <sup>3</sup>Department of Veterinary Microbiology, Ahmadu Bello University, Zaria, Kaduna, Nigeria.



**\*Corresponding author:**

Talatu Patience Markus,  
Microbiology Specialty,  
Pathology Faculty, College of  
Veterinary Surgeons of Nigeria,  
Zaria Study Centre, Zaria,  
Kaduna, Nigeria.

[talatupmarkus@gmail.com](mailto:talatupmarkus@gmail.com)

Received: 17 November 2024

Accepted: 27 November 2024

Published: 14 January 2025

**DOI**

10.25259/RVSM\_15\_2024

**Quick Response Code:**



### ABSTRACT

This manuscript presents a case of multidrug-resistant (MDR) bacterial infections in the respiratory system of a 6-year-old Arewa stallion, thus highlighting the importance of diagnostic microbiology. History revealed that the stallion exhibited clinical signs, including high fever, hemoglobinuria, and edema of the head and neck, and this was followed by death despite medical intervention. Postmortem was pneumonia; hence lung sample was sent for microbiological analyses. The diagnostic microbiological techniques utilized were culture on blood MacConkey and Eosin Methylene Blue agars, and biochemical tests were used to confirm the bacterial identities, followed by antibiotic susceptibility testing. The outcomes revealed the isolation of *Corynebacterium* spp., *Escherichia coli*, and *Klebsiella* spp. Antibiotic susceptibility testing revealed extensive resistance, with *Corynebacterium* spp. resistant to Septrin, Chloramphenicol, Sparfloxacin, Ciprofloxacin, and more. *E. coli* and *Klebsiella* spp. were resistant to Ciprofloxacin, Gentamicin, Nitrofurantoin, Ofloxacin, Cefuroxime, Ceftazidime, Augmentin, and Cotrimoxazole. These findings emphasize the diagnostic challenges caused by MDR pathogens in equine respiratory diseases.

**Keywords:** Antibiotic susceptibility testing, Cultural isolation, Diagnostic microbiology, Equine respiratory diseases, Multidrug resistance

### INTRODUCTION

Diagnostic microbiology plays a crucial role in veterinary medicine by enabling the identification of pathogens responsible for infectious diseases, thus guiding appropriate treatment strategies.<sup>[1]</sup> In equine practice, respiratory infections are a significant concern due to their impact on animal health and performance.<sup>[2]</sup> The emergence of multidrug-resistant (MDR) bacteria poses a severe challenge to treatment efficacy, thus making timely and accurate microbial diagnosis even more critical.<sup>[3]</sup> This report highlights the complexities of managing a case of MDR bacterial infection in a 6-year-old Arewa stallion, emphasizing the importance of diagnostic microbiology in devising effective therapeutic interventions.

This case report provides critical insights into the diagnostic challenges posed by MDR bacterial infections in equine respiratory diseases. The findings align with current trends in veterinary microbiology, thus highlighting the need for comprehensive diagnostic protocols, including necropsy, culture, biochemical testing, and antibiotic susceptibility testing. By presenting this

This is an open-access article distributed under the terms of the Creative Commons Attribution-Non Commercial-Share Alike 4.0 License, which allows others to remix, transform, and build upon the work non-commercially, as long as the author is credited and the new creations are licensed under the identical terms.

©2025 Published by Scientific Scholar on behalf of Research in Veterinary Science and Medicine

case, we aim to shed light on the evolving scope of antibiotic resistance in equine respiratory diseases and the pivotal role of diagnostic microbiology in addressing these challenges, to ultimately improve animal health outcomes.

## CASE REPORT

A lung sample was obtained from the carcass of a 6-year-old Arewa stallion presented to the Necropsy Unit, Veterinary Teaching Hospital, and submitted to the Bacteriology Laboratory, Department of Veterinary Microbiology, Ahmadu Bello University Zaria, Nigeria. History revealed that the nail was removed from the left forelimb, and tetanus toxoid was administered 3 weeks before the presentation of the stallion to the Large Animal Clinic. The clinical signs observed were hemoglobinuria, sweating, high temperature (41°C), congested ocular mucous membrane, dilation of the nostrils, restlessness, recumbency, and generalized edema around the head and neck. The medications administered were imidocarb dipropionate, benzyl penicillin, intravenous dextrose saline, xylazine, diclofenac, and multivitamin, and the feed were hay and bran (wheat offal).

The stallion died 2 days after being sick and recumbent, and the carcass was transported to the Necropsy unit for postmortem examination. The gross findings were a slightly enlarged heart with a chicken fat clot in the right ventricle; congested, hemorrhagic and hepatized lungs; hemorrhagic trachea with frothy exudates; enlarged and congested liver; enlarged spleen; severe hemorrhagic gastroenteritis with helminths in the colon; and congested kidneys.

### Microbiological examinations

#### Culture and isolation

The surface of the lung sample was seared with a sterilized spatula and a loop was used to culture on blood and MacConkey agars and incubated at 37°C for 24 h and later observed for colonies. Presumptive colonies of *E. coli* were then sub-cultured onto Eosin Methylene Blue (EMB) agar.

#### Biochemical test

The isolates presumptive of *E. coli* and *Klebsiella* spp. was inoculated into Triple Sugar Iron, Indole, Urea, Citrate, Methyl Red, Voges Proskauer and motility and incubated for 24 h at 37°C.

#### Catalase test

This was performed using a sterilized loop to pick from the colony on blood agar and placing on a clean glass slide. This was followed by addition of a drop of hydrogen peroxide on

the colony and observation for bubble formation which is indicative of a positive reaction.

#### Antibiotic susceptibility test

Disc diffusion method was used for antibiotic sensitivity testing of the isolates. Mueller–Hinton agar was used, and the gram positive was smeared with a cotton swab onto the Mueller–Hinton agar. Then, using a sterilized forcep, a Gram-positive antibiotic sensitivity disc was picked and placed onto the media and incubated for 24 h at 37°C. The same procedure was repeated for the Gram-negative isolates.

#### Outcome of culture and isolation

Three organisms were isolated from the lungs of the horse. The first isolate appeared as small, grayish, non-hemolytic colonies on blood agar and did not grow on MacConkey. The isolate was gram-positive rods with a Chinese letter-like appearance [Figure 1], presumptive for *Corynebacterium* spp.

The second isolate appeared as medium-sized, smooth, raised, whitish non-hemolytic colonies on blood agar, which was pinkish on MacConkey (lactose fermenter), produced a greenish metallic sheen on EMB [Figure 2a], gram-negative rods [Figure 2b], suggestive of *E. coli*. The third isolate appeared as gray, small, mucoid, non-hemolytic colonies on blood agar, pink, mucoid colonies on MacConkey [Figure 3a] and Gram-negative short rods [Figure 3b] presumptive for *Klebsiella* spp.

#### Biochemical test results

The biochemical test identified the second isolate as *E. coli* and the third as *Klebsiella* spp. [Table 1 and Figure 4].

#### Catalase test reaction

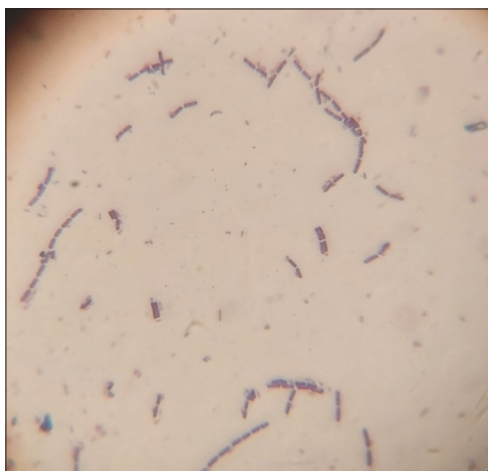The presumptive isolate of *Corynebacterium* spp. was catalase positive.

#### Antibiotic susceptibility test

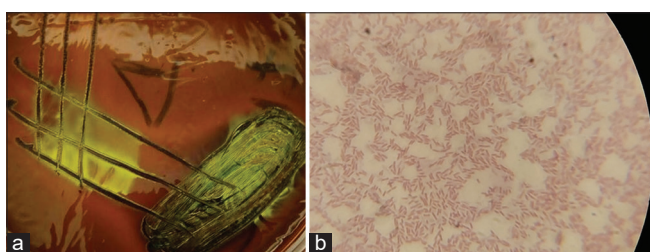
*Corynebacterium* spp. was resistant to all the antibiotics used (Septrin, Chloramphenicol, Sparfloxacin, Ciprofloxacin, Amoxicillin, Augmentin, Gentamicin, Pefloxacin, Tarivid, Streptomycin). *E. coli* and *Klebsiella* spp. were also resistant to all the antibiotics used (Ciprofloxacin, Gentamicin, Nitrofurantoin, Ofloxacin, Cefuroxime, Ceftazidime, Augmentin, Co-trimoxazole).

## DISCUSSION

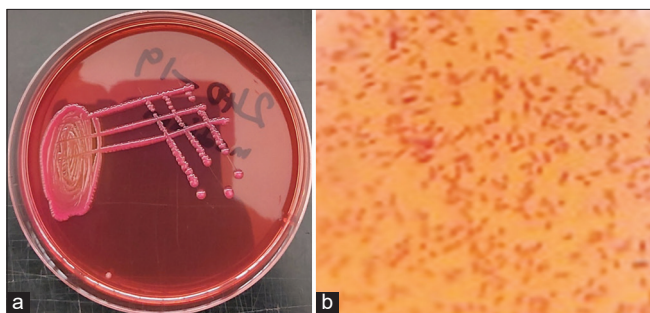
The isolation of *Corynebacterium* spp., *E. coli*, and *Klebsiella* spp. from the lungs of the stallion highlights the complex interplay of bacterial pathogens in severe equine respiratory infections.<sup>[4]</sup> The case presented a rapid progression of clinical symptoms,




**Figure 1:** Gram-positive rods with the shape of Chinese letters, presumptive for *Corynebacterium* spp (Grams stain, X100 Magnification).



**Figure 2:** (a) Colonies with greenish metallic sheen on eosin methylene blue agar; and (b) Gram-negative rods, presumptive for *Escherichia coli* (Grams stain, X100 Magnification).



**Figure 3:** (a) Small size, pink, mucoid colonies on MacConkey agar; and (b) Gram-negative short rods, presumptive for *Klebsiella* spp (Grams stain, X100 Magnification).



**Figure 4:** (a) Biochemical test outcome of *Escherichia coli* (b) Biochemical test outcome of *Klebsiella* spp. From L-R (a & b): Triple Sugar Iron, Indole, Urease, Citrate, Methyl Red, Voges Proskauer and motility.

**Table 1:** Outcome of biochemical test on isolates presumptive of *Escherichia coli* and *Klebsiella* sp.

S/N	Biochemical test	Isolate II	Isolate III
1	TSI	Acid/acid+gas	Acid/acid+gas
2	Indole	Positive	Negative
3	Citrate	Negative	Positive
4	Urea	Negative	Positive
5	Methyl red	Positive	Negative
6	Voges Proskauer	Negative	Positive
7	Motility	Motile	Non-motile
		<i>Escherichia coli</i>	<i>Klebsiella</i> spp.

TSI: Triple sugar iron

including systemic inflammation (generalized edema), severe respiratory distress, and multisystemic involvement, ultimately leading to mortality within 2 days of onset. The observed history of tetanus toxoid administration following the removal of a nail from the forelimb suggests that the animal was already immunologically challenged, potentially predisposing it to secondary infections. In addition, the clinical signs such as hemoglobinuria, fever (41°C), restlessness, and recumbency point toward systemic toxemia and organ failure.<sup>[5,6]</sup>

Postmortem examination revealed gross pathological changes consistent with a severe, multifocal bacterial infection. The findings of hepatized lungs, frothy exudates in the trachea, and congested organs, combined with hemorrhagic gastroenteritis and helminth infestation, suggest a state of overwhelming sepsis. Isolation and identification of the pathogens confirmed their involvement in the disease process. *Corynebacterium* spp., characterized by its unique Chinese letter-like appearance and catalase positivity, is known for its opportunistic pathogenicity in immunocompromised animals. The presence of *E. coli* and *Klebsiella* spp., both facultative pathogens, indicates possible aspiration or hematogenous spread, contributing to severe pulmonary infection and systemic dissemination.<sup>[7,8]</sup>

Antibiotic resistance profiles of the isolated bacteria further complicated the therapeutic management of the case. The resistance of all three isolates to multiple antibiotics, including commonly used agents such as ciprofloxacin, gentamicin, and amoxicillin, underscores the growing challenge of antimicrobial resistance in veterinary medicine.<sup>[9]</sup> It reiterates the importance of infection control and supportive care in managing systemic infections.<sup>[10]</sup>

## CONCLUSION

This case emphasizes the critical challenge of MDR bacterial infections in equine medicine, highlighting the need for prompt diagnosis, effective treatment, and antimicrobial stewardship. It reiterates the need for ongoing surveillance and research into resistance patterns in veterinary pathogens.

**Ethical approval:** Institutional Review Board approval is not required.

**Declaration of patient consent:** Patient's consent not required as there are no patients in this study.

**Financial support and sponsorship:** Nil.

**Conflicts of interest:** There are no conflicts of interest.

**Use of artificial intelligence (AI)-assisted technology for manuscript preparation:** The authors confirm that there was no use of artificial intelligence (AI)-assisted technology for assisting in the writing or editing of the manuscript and no images were manipulated using AI.

## REFERENCES

1. Wang H, Zhang W, Tang YW. Clinical Microbiology in Detection and Identification of Emerging Microbial Pathogens: Past, Present and Future. *Emerg Microbes Infect* 2022;11:2579-89.
2. Pusterla N, James K, Barnum S, Bain F, Barnett DC, Chappell D, *et al.* Frequency of Detection and Prevalence Factors Associated with Common Respiratory Pathogens in Equids with Acute Onset of Fever and/or Respiratory Signs (2008-2021). *Pathogens* 2022;11:759.
3. Nwobodo DC, Ugwu MC, Oliseloke AC, Al-Ouqaili MT, Chinedu IJ, Victor CU, *et al.* Antibiotic Resistance: The Challenges and Some Emerging Strategies for Tackling a Global Menace. *J Clin Lab Anal* 2022;36:e24655.
4. Mach N, Baranowski E, Nouvel LX, Citti C. The Airway Pathobiome in Complex Respiratory Diseases: A Perspective in Domestic Animals. *Front Cell Infect Microbiol* 2021;11:583600.
5. Taylor S. A Review of Equine Sepsis. *Equine Vet Educ* 2015;27:99-109.
6. Blangy-Letheule A, Vergnaud A, Dupa, T, Rozec B, Lauzier B, Leroux AA. Spontaneous Sepsis in Adult Horses: From Veterinary to Human Medicine Perspectives. *Cells* 2023;12:1052.
7. Bianchi MV, Mello LS, Ribeiro PR, Wentz MF, Stolf AS, Lopes BC, *et al.* Causes and Pathology of Equine Pneumonia and Pleuritis in Southern Brazil. *J Comp Pathol* 2020;179:65-73.
8. Borum AE. Agents Isolated from Horses with Respiratory System Infection Signs. *Etlik Vet Mikrobiyol Derg* 2022;33:56-62.
9. Venturini C, Bowring B, Partridge SR, Ben Zakour NL, Fajardo-Lubian A, Lopez Ayala A, *et al.* Co-Occurrence of Multidrug Resistant *Klebsiella pneumoniae* Pathogenic Clones of Human Relevance in an Equine Pneumonia Case. *Microbiol Spectr* 2022;10:e0215821.
10. Isgren CM. Improving Clinical Outcomes via Responsible Antimicrobial Use in Horses. *Equine Vet Educ* 2021;34:482-92.

**How to cite this article:** Markus TP, Orakpoghenor O, Mamman PH. Multidrug-Resistant *Corynebacterium* spp., *Escherichia coli*, and *Klebsiella* spp. Isolated from the Lungs of a Six Year-Old Arewa Stallion. *Res Vet Sci Med.* 2025;15:1. doi: 10.25259/RVSM\_15\_2024