



Case Report Surgery

## Surgical Management of Left-Hand Traumatic Injury in an Adult Female Captive Chimpanzee (*Pan troglodytes*): A Case Report

Daniel Onimisi Avazi<sup>1</sup>, Onuche Shalom Agweche<sup>2</sup>, Daphne Peter Habila<sup>3</sup>, Samuel Adeola Babalola<sup>1</sup>

<sup>1</sup>Department of Veterinary Medicine, Surgery and Radiology, University of Jos, <sup>2</sup>Departments of Clinical Pharmacology, <sup>3</sup>Medicine, Surgery and Radiology, Veterinary Teaching Hospital, University of Jos, Jos, Nigeria.



**\*Corresponding author:**

Daniel Onimisi Avazi,  
Department of Veterinary  
Medicine, Surgery and  
Radiology, University of Jos,  
Jos, Nigeria.

[danoovavaz@gmail.com](mailto:danoovavaz@gmail.com)

Received: 27 February 2024

Accepted: 30 July 2024

Published: 19 September 2024

DOI

10.25259/RVSM\_3\_2024

Quick Response Code:



### ABSTRACT

Captive chimpanzees are reported to present a higher frequency of injuries compared to those obtained in the wild due to their intraspecific aggression. Wounds are inescapable events in life following physical, chemical, thermal, microbial, or immunological insult to a body tissue, resulting in disruptions, breakage and loss of cellular and anatomical or functional continuity of living tissues or organs. The attention of the Veterinary Teaching Hospital, University of Jos was drawn to an injured adult female chimpanzee at the Jos Zoo. History revealed that the wound was the result of aggression from a counterpart chimpanzee. History reveals also that the wound was managed for 1 month before presentation with no significant improvement. Close examination revealed degloved left index and ring digits with pussy discharges. Assessment of the wound was undertaken after chemical immobilization and the resulting defects were reconstructed following proper aseptic surgical preparation utilizing chlorhexidine gluconate (Purit®) and amputation of the non-viable segments of the affected digits. Postoperatively, daily cleaning and administration of oxytetracycline spray (topical), doxycycline capsules 5 mg/kg  $\times^{1/52}$  PO and Dolometa B®  $\times^{2/7}$  PO were instituted. This case demonstrated the important role of prompt and thorough clinical evaluation in the adoption of management options, especially in wildlife management.

**Keywords:** Amputation, Anesthesia, Chimpanzee, Digit, Traumatic injuries

### INTRODUCTION

Chimpanzees are particularly long-lived animals that are phylogenetically close to humans especially in social interactions, care, and management.<sup>[1]</sup> However, reports by researchers of frequent and higher levels of aggressive behaviors with injuries among captive chimpanzees than those in the wild populations demand for investigation so as to improve care for the managed population of chimpanzees.<sup>[2,3]</sup> The continued presence of human visitors with different affiliative behaviors and countenances are strong determinants of relationship value and compatibility. In the wild, chimpanzees are bedeviled by risks such as encounters with poachers and snares, accidents from crossing busy roads, predators such as Lions and Hyenas, etcetera. In general, Apes in managed care settings battle with a wide range of cardiovascular-related health problems such as periodontitis, hypertension, renal disease, and cerebral vascular diseases, which have been repeatedly confirmed as the most frequent cause of death following traumatic injuries.<sup>[4,5]</sup>

This is an open-access article distributed under the terms of the Creative Commons Attribution-Non Commercial-Share Alike 4.0 License, which allows others to remix, transform, and build upon the work non-commercially, as long as the author is credited and the new creations are licensed under the identical terms.

©2024 Published by Scientific Scholar on behalf of Research in Veterinary Science and Medicine

Traumatic wounds have been identified as a distinct prevalent extrinsic cause of death for chimpanzees in the wild and captivity under managed care, in addition to complicating infectious factors, including those that are zoonotic in nature.<sup>[1,6]</sup> The wound is also defined as a loss or breakage of cellular and anatomical or functional continuity of living tissue following physical, chemical, thermal, microbial, or immunological insult to the body.<sup>[7]</sup> As observed by Gauthier<sup>[2]</sup> and Ross *et al.*,<sup>[1]</sup> affiliative behaviors, such as grooming, touching, close spatial proximity, and playing, reduce aggressive encounters such as anxiety, fight, and supplants in captive chimpanzees. Magden *et al.*<sup>[8]</sup> reported oral lavender therapy in managing injured chimpanzees to decrease the percentage of wounds requiring medical intervention due to its stress relieving effect.

## CASE REPORT

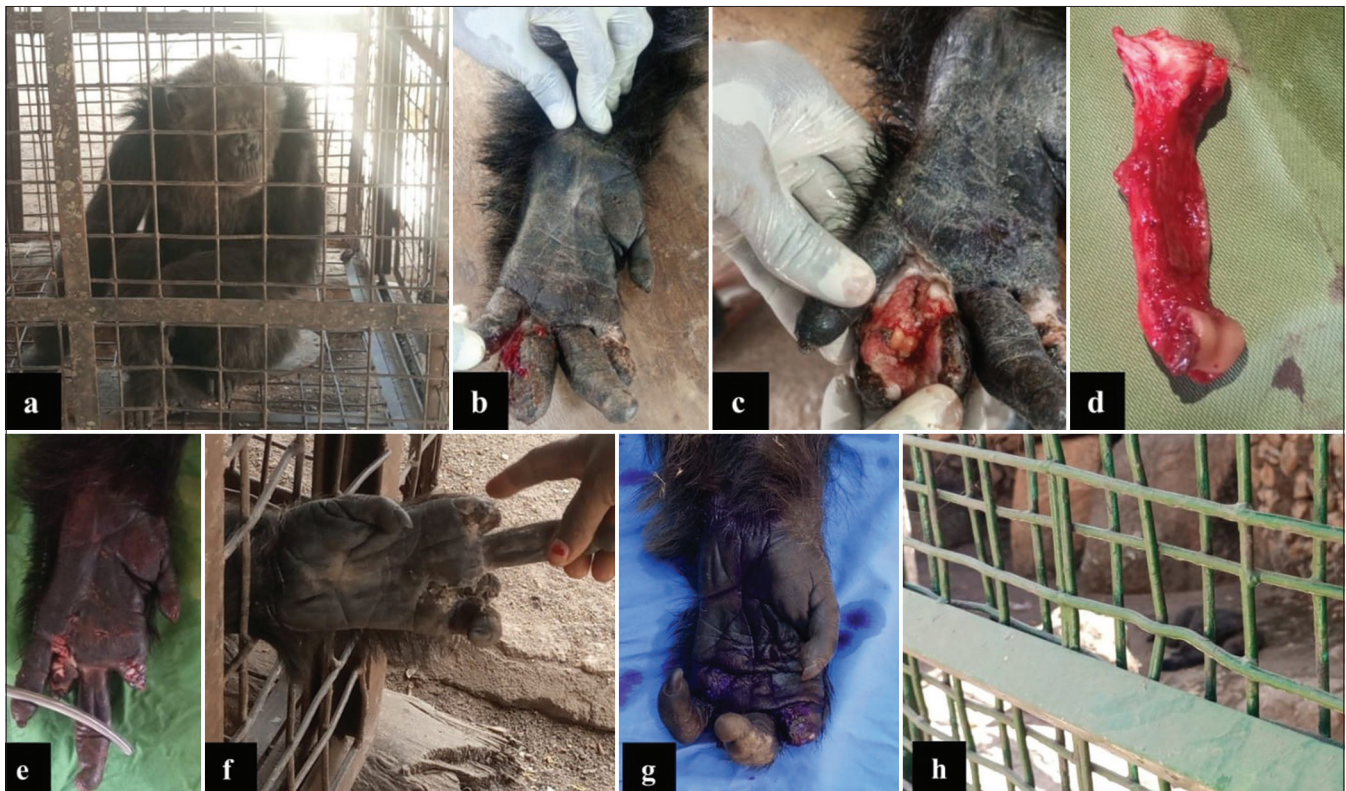### History and clinical examination

The attention of the Veterinary Teaching Hospital, University of Jos, was drawn to a 42 kg injured adult female chimpanzee at the Jos Zoo. The multiple wounds were reported as bite wounds sustained as a result of aggression

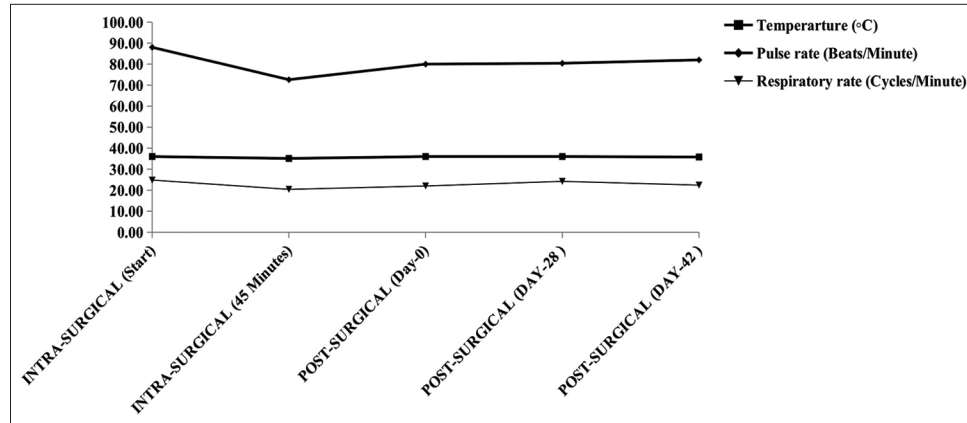
from a counterpart chimpanzee during feeding. History also revealed that the wound was managed with antibiotic spray by the zoo attendants 1 month before presentation with no significant improvement except for the normal appetite. On close examination, the chimpanzee appeared active with good appetite and mentation; also, there were missing/lost proximal and middle phalanges of the left index and ring digits with pussy discharges around the injuries.

### Management

The chimpanzee was lured into a squeeze cage, immobilized, and anesthetized [Figure 1a]. Analgesia and anesthesia were, respectively, achieved using Pentazocine (Pentalab® - Laborate Pharmaceuticals Ltd., India) at 1 mg/kg intramuscularly and 50 mg/mL ketamine hydrochloride (Jawa ketamine® - Swiss Parenterals Ltd., Gujarat, India) at 12 mg/kg + 2% Xylazine (Alfasan, Woerden-Holland) at 0.2 mg/kg intramuscularly. Three milliliters of whole blood was collected and dispensed into anticoagulant (Ethylenediamine tetraacetic acid) containing sample bottles which were used for hematology by an automated hematology analyzer (Mindray® BC-3600, Shenzhen, China). Critical assessment of the wound



**Figure 1:** Appraisal of digital amputation and wound management in an adult female chimpanzee. (a) Captured chimpanzee in a squeeze cage immediately following administration of anesthetics, (b) wound appearing desiccated before cleansing, (c) wound appearance after cleansing with soap, water and antiseptics, (d) disarticulated first phalanx of the left ring digit, (e) appearance of left-hand immediately following amputation of index and ring digits, (f) significantly healed wounds 2 weeks post-operation, (g) appearance 4 weeks post-operation, and (h) chimpanzee in the Zoo's sanctuary setting on day 42 post-operation.



**Figure 2:** Peri-surgical vital parameters of rectal temperature, pulse and respiratory rates during digital amputation, and wound management in an adult female chimpanzee.

[Figure 1b] was undertaken with the full extent of damage evident following proper cleansing and decontamination with Chlorhexidine gluconate (Purit®) [Figure 1c]; thus, the adoption of amputation of the non-viable digits became the most viable option. The index and ring digits of the left-hand (with already lost proximal and middle phalanges) were dissected to expose the metacarpophalangeal joints from which the digits were disarticulated and the resulting defects reconstructed using size 1 vicryl® suture apposing the surrounding tissues, while closing dead spaces and re-approximating the wound edges by simple continuous and intradermal suture patterns, respectively [Figure 1d and e]. The surgical site was sprayed with 10% oxytetracycline and the chimpanzee was administered with injection Tetatox® (TT Vaccine) 0.5 mL IM  $\times 1/7$ , injection 1% piroxicam at 0.3 mg/kg IM  $\times 1/7$  and 10% oxytetracycline 20 mg/kg IM  $\times 1/7$ , and injection 1% ivermectin 0.6 mg/kg SC once weekly  $\times 2/52$ . Postoperatively, daily application of 10% oxytetracycline spray on the surgical site, doxycycline capsules 5 mg/kg  $\times 7/7$ , and Dolo-meta-B® (Vitamins B<sub>1</sub>+B<sub>4</sub>+B<sub>12</sub>+Diclofenac Sodium)  $\times 5/7$  orally were administered. The chimpanzee was immobilized fortnightly for re-assessment of healing and was finally relocated back to the Zoo's sanctuary setting by day 42 post-operation [Figure 1f-h]. The peri-surgical vital parameters of rectal temperature, pulse and respiratory rates during the management periods are as shown in Figure 2.

## DISCUSSION

On the surface, it may appear strange that despite the initial wound management by use of oxytetracycline spray in this case, disturbances of healing persisted. Although antiseptic and antibiotics are vital agents successful in wound management, adherence to the guidelines of the procedural ethics of wound examination and management are essential tools for a positive impact with the desired final clinical outcome.<sup>[9]</sup> Wound management begins with a complete

and detailed examination of the patient to assess, ascertain, and document the wound's etiology, environment, and nature. These aid in the optimization of the patient's medical condition, particularly diagnosis of life-threatening injuries, any underlying conditions such as exposed delicate tissues such as nerves, vascular supply, tendons, visceral organs, and bones. The management of such results in the restoration of blood flow to the wound area may be achieved by proper wound cleansing and debridement.<sup>[7,9]</sup> In this case, a critical close assessment of the injured limb revealed devitalized soft tissue and proximal index and ring phalangeal bones, as well as infection, which all together served as a guide to the informed choice of management by amputation. The packed cell volume of 38% was within the normal reference established by Howell *et al.*<sup>[10]</sup> Furthermore, the observed neutropenia and lymphocytosis in the leucogram is classical of chronic inflammation corroborating the reports by Witte and Barbul<sup>[9]</sup> and strengthening the history of the wound being sustained for some weeks with no progressive healing following initial management. The instituted debridement coupled with irrigation of the wound aided the removal of dead, infected and hyperkeratotic tissues, as well as foreign materials on from the wound surface. This forms the basis of non-delayed as well as delayed wound healing as a vascularization of tissues prevents leukocytes, cytokines, growth factors, and other humoral factors that would have otherwise helped in infection control and hemostasis from gaining access to the wound site, thus the need to debride thereby accelerating wound healing as recorded in this case.<sup>[7,9]</sup> Furthermore, the antibiogram susceptibility guided the choice of antibiotic administration in this case as this chimpanzee was in captivity as against their wild counterparts reported to engage in self-medication, suppressing or preventing the deleterious effects of parasitism and other frequent causes of illness through behavioral means.<sup>[8]</sup>

## CONCLUSION

In conclusion, prompt intervention, thorough clinical examination, informed decision on wound management options and protocol, gentle but proper tissue handling and consistent wound care coupled with rational drugs use are essentials to achieve a timely and uneventful wound healing especially in captive chimpanzees.

### Acknowledgments

The author appreciates the immense contributions of Mrs. OhaegbuM, for granting the permission to publish this case and Mr. James G and Mr. AbdulkareemYI for assisting with the laboratory analysis.

### Ethical approval

The Institutional Review Board approval is not required.

### Declaration of patient consent

Patient's consent not required as there are no patients in this study.

### Financial support and sponsorship

Nil.

### Conflicts of interest

There are no conflicts of interest.

### Use of artificial intelligence (AI)-assisted technology for manuscript preparation

The authors confirm that there was no use of artificial intelligence (AI)-assisted technology for assisting in the writing or editing of the manuscript and no images were manipulated using AI.

## REFERENCES

1. Ross SR, Joshi PB, Terio KA, Gamble KC. A 25-Year Retrospective Review of Mortality in Chimpanzees (*Pan troglodytes*) in Accredited U.S. Zoos from A Management and Welfare Perspective. *J Anim* 2022;12:1878-90.
2. Gauthier C. Does Affiliation Reduce Aggression in Captive Chimpanzees? A Thesis Presented to California State University, Fullert in Partial Fulfillment of the Degree: Masters of Arts, Evolutionary Anthropology. 2021. p. 1-61.
3. Fultz A, Yanagi A, Breaux S, Beaupre L. Aggressive, Submissive, and Affiliative Behavior in Sanctuary Chimpanzees (*Pan troglodytes*) during Social Integration. *J Anim* 2022;12:2421-44.
4. Che-Castaldo J, Havercamp K, Watanuki K, Matsuzawa T, Hirata S, Ross SR. Comparative Survival Analyses among Captive Chimpanzees (*Pan troglodytes*) in America and Japan. *Peer J* 2021;9:e11913.
5. Gamble KC, Terio KA. Chimpanzee Mortality Review: 25 Years. In: Miller RE, Lamberski N, Calle PC, editors. *Fowler's Zoo and Wild Animal Medicine*. Vol. 10. Ch. 98. St. Louis, MO, USA: Elsevier; 2022.
6. Terio KA, Kinsel MJ, Raphael J, Mlengeya T, Lipende I, Kirchhoff CA, et al. Pathologic Lesions in Chimpanzees (*Pan troglodytes schweinfurthii*) from Gombe National Park, Tanzania, 2001-2010. *J Zoo Wild Med* 2011;42:597-607.
7. Avazi DO, Awasum CA, Hassan AZ, Ayo JO, Aluwong T, Muhammed ST, et al. Evaluation of Levels of Interleukin-6, Interleukin-8 and Some Haematologic Parameters of Dogs with Cutaneous Wounds. *Cytokine* 2019;113:128-38.
8. Magden ER, Neal Webb S, Lambeth SP, Buchl SJ, Schapiro SJ. The Effects of Oral Lavender Therapy on Wounding in Chimpanzees (*Pan troglodytes*). *J Anim* 2023;13:1382-93.
9. Park JE, Barbul A. Understanding the Role of Immune Regulation in Wound Healing. *Am J Surg* 2004;187:11S-16.
10. Howell S, Hoffman K, Bartel L, Schwandt M, Morris J, Fritz J. Normal Hematologic and Serum Clinical Chemistry Values for Captive Chimpanzees (*Pan troglodytes*). *Comp Med* 2023;53:413-23.

**How to cite this article:** Avazi DO, Agweche OS, Habila DP, Babalola SA. Surgical Management of Left-Hand Traumatic Injury in an Adult Female Captive Chimpanzee (*Pan troglodytes*): A Case Report. *Res Vet Sci Med*. 2024;4:3. doi: 10.25259/RVSM\_3\_2024